

[3rd Molar Surgery Course / Sedation Course]

Faculty of Dentistry - International Postgraduate Medical College]



**Limited Attendance to 10
Dentists Only!!!**

Location: Montego Bay

Course Components:

1. E-Distance learning on:

- A. Zoom
- B. Tablet.

2. Direct Contact Teaching (Power Point Lectures), Round table discussions and Seminars

3. Laboratory Hands-on by both:

- a. E-distance learning and
- b. Direct Laboratory supervision

4. Live Surgery

**Course Fee: 5,000 USD (for Jamaicans)
Others- 10,000 USD**

Course Date: January, February April 2022

to apply Email: internationalpostgradmed@gmail.com or WhatsApp/Call: 876-

**Fellow American College of Oral & Maxillofacial Surgeons
Diplomate- International Congress of Oral Implantologists.**

DAY 1[Back to top](#)

SESSION 1		LECTURER
09:00	<ol style="list-style-type: none">1. Clinical indication for third molar surgery.2. Classification of impacted 3rd Molar3. Is prophylactic removal an indication.....yes or no?4. Radiological assessment of the third molar.5. Clinical and radiological errors in pre-operative assessment5. Is Coronectomy an acceptable treatment?6. Surgical technique for coronectomy7. Equipment and instrumentation for third molar surgery8. Aseptic technique in 3rd Molar Surgery	Dr. C. Ogunsalu
12:00 LUNCH		
13:00*	<ol style="list-style-type: none">1. Surgical Technique for 3rd molar surgery2. GTR and 3rd Molar Surgery!3. Local anaesthesia Vs Local anaesthesia + sedation 3. Third molar surgery under general anesthesia 4. Pharmacology of third molar surgery	

	<i>Radiological assessment (Clinical & RTD)</i>	Dr. C. Ogunsalu
--	---	-----------------

DAY 2

[Back to top](#)

SESSION 1		LECTURER
09:00	6. Pathologies associated with 3 rd molar surgery - dentigerous cyst - Ameloblastoma - OKC etc 7. Complications associated with 3 rd molar surgery	Dr Christopher Ogunsalu
	Avoiding the IDN	
	Assessing the IDN	
12:00 LUNCH		
13:00	8. Cryotherapy and 3 rd molar surgery 10. Current concepts and controversies	
14:00	Surgical Lab Hands -on	
16:00	Surgical Lab Hands-on	Dr. Christopher Ogunsalu

Round Table Discussion (RTD)

1. Nerve morbidity following wisdom tooth removal under local and general anaesthesia
2. Evaluation of factors predictive of lingual nerve injury in 3rd molar surgery

SESSION 1		LECTURER
09:00	<ol style="list-style-type: none"> 1. Routine review of patients after 3M EXTRACTION 2. Fracture after 3M Removal 3. Pell-Gregory classification ...is it reliable? 4. Nerve morbidity following wisdom teeth removal under local and general anesthesia 5. Evaluation of factors predictive of lingual nerve injury in 3rd molar surgery 6. Surgical Transplantation of the 3rd Molar 	<p>Dr Christopher Ogunsalu</p>
10:00*	LIVE SURGERY	<p><i>Clinical Instructor – To be announced</i></p>
11:00*	LIVE SURGERY	<p><i>Clinical instructors – To be announced</i></p>
12:00	LUNCH	
13:00*	LIVE SURGERY	
14:00		
15:00		

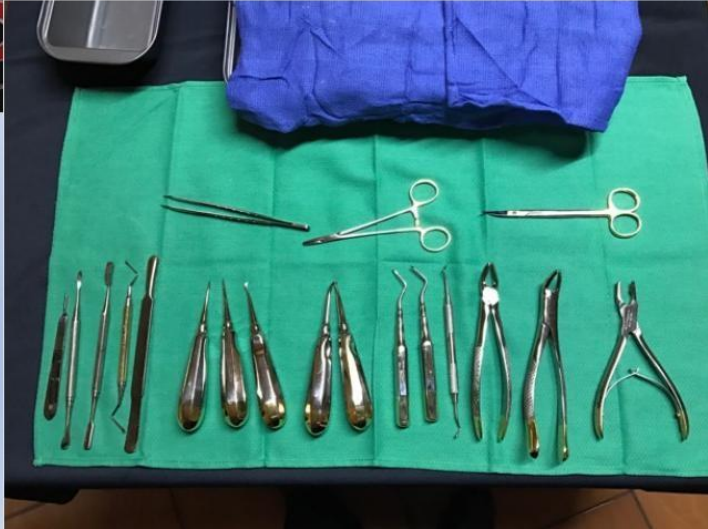

Instruments from MEDCO
Contact: Jeff Jaffary
708-860-7413



To be added:

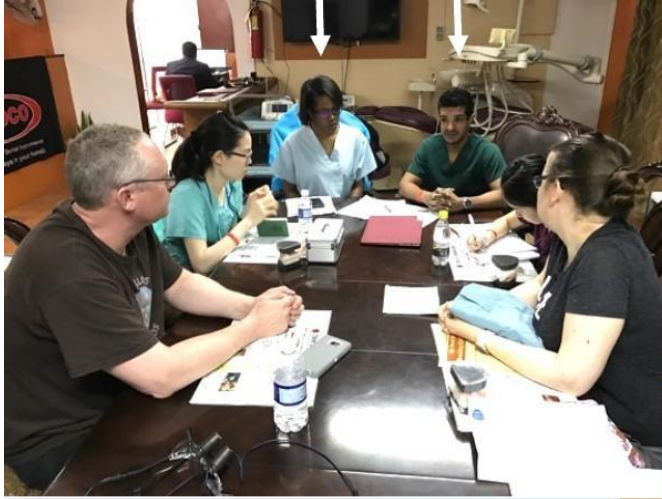- Tissue pickups (Adson-Brown 43)
- Curved Kelly hemostat
- Cotton plier (remove the Russian forcep)
- Cowhorn (23)



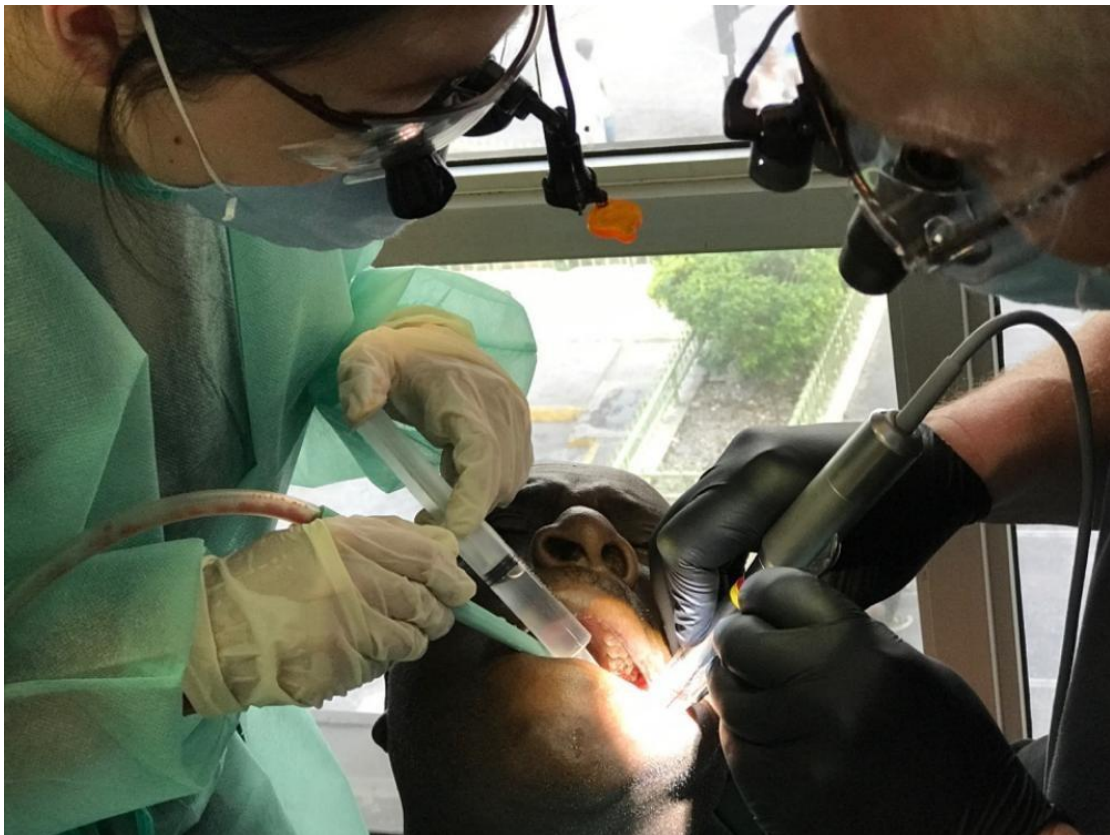Teaching area:

- Didactic
- Models

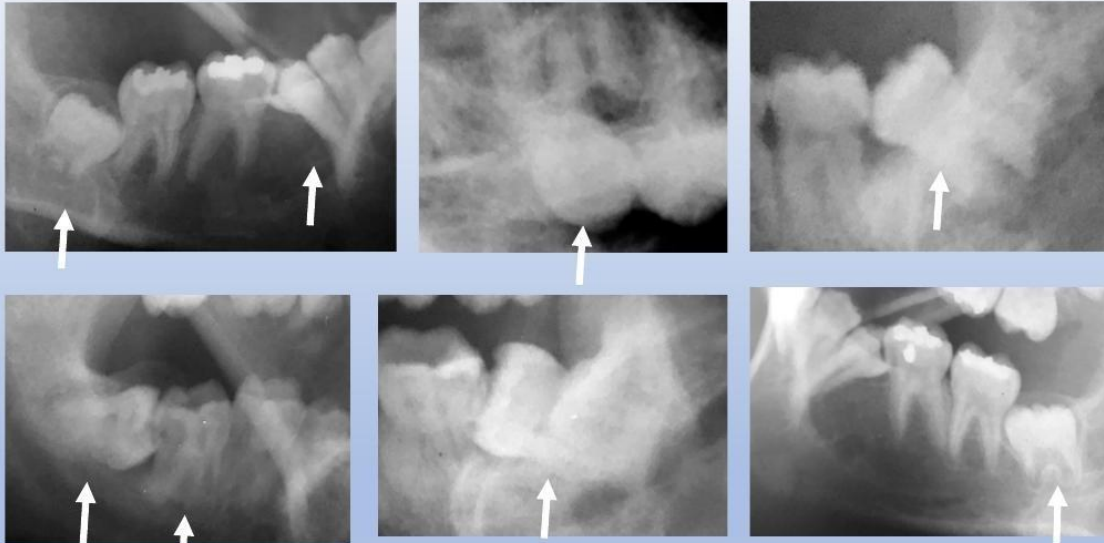




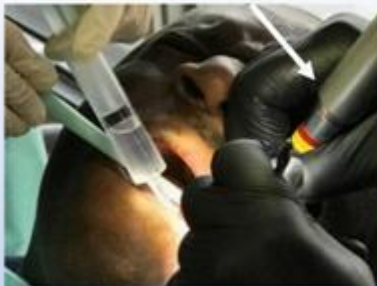Besides teaching by Dr. Koerner, also teaching by Dr. Lissa Pinkney-Gayle and Dr. Arif Saqui – residents in the College.



Some patients our patients needing treatment

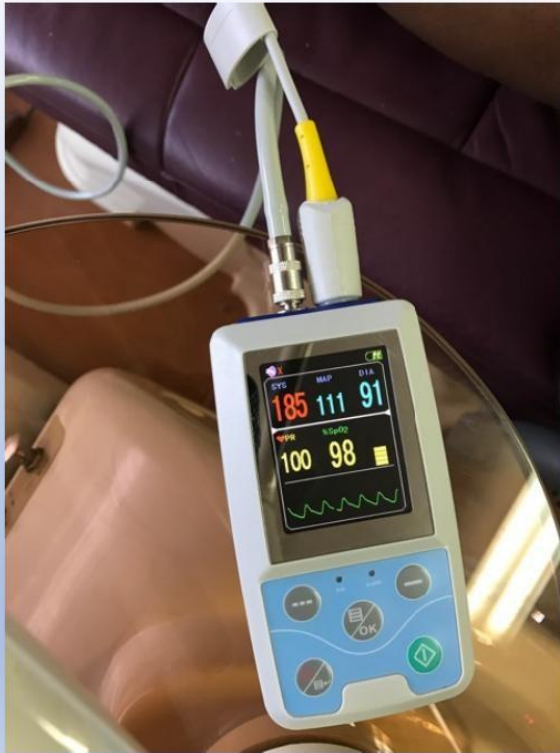

Most patients were from the community who needed treatment now and did not want to wait (a few months) to get into the free public dental clinics.

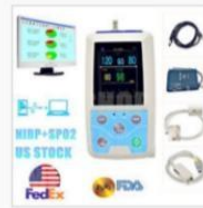

Use of the straight handpiece
OR could also use the "surgical"
highspeed



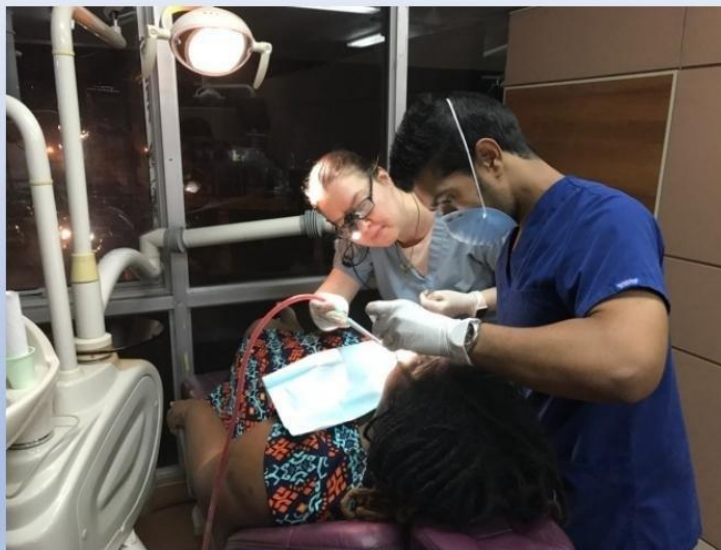

This patient was refused treatment because her blood pressure was too high

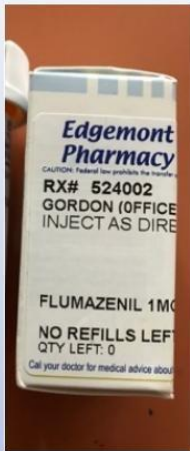

CONTEC PM50
Portable Blood Pressure
NIBP/Spo2
Patient Monitor+Cuff+Probe NEW

Working into the night to see waiting patients in need and accomplish the most treatment possible.

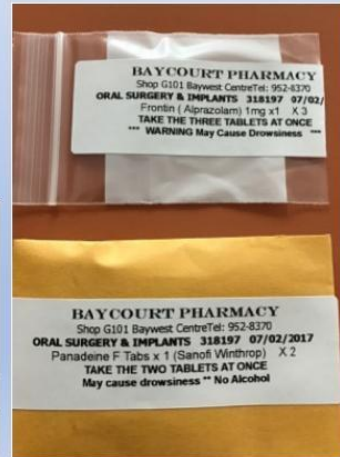
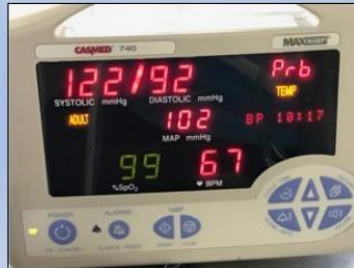

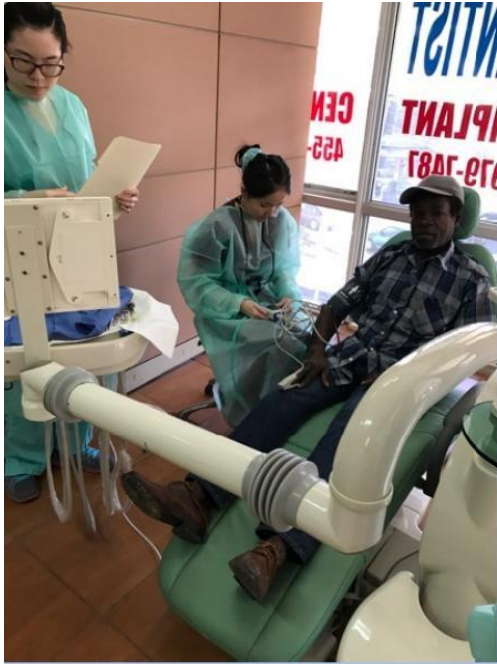Resident stepping in to offer a different approach to a difficult case.



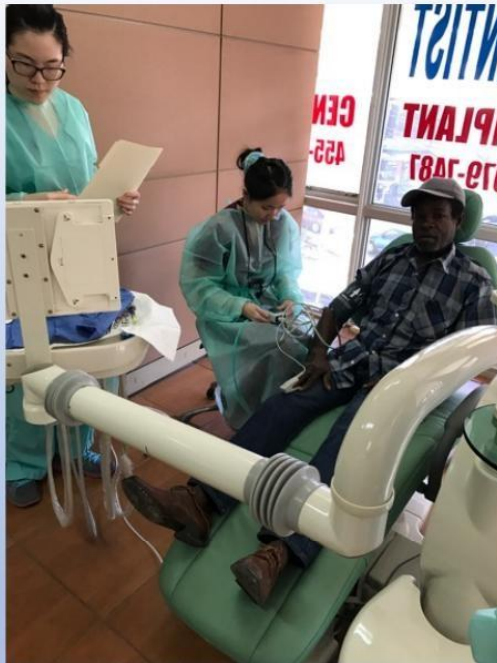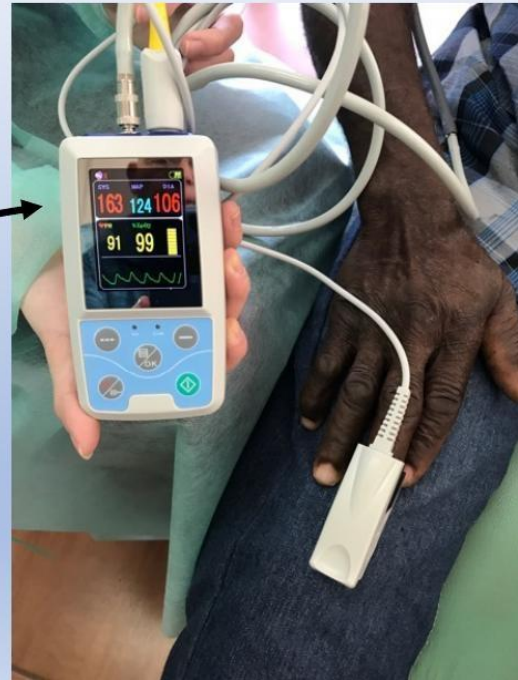Oral Sedation:

- Triazolam (up to 0.5 mg), OR
- Local practice: 2-3 mg alprazolam [Xanax] + acetaminophen with codeine
- Reversal agent
- Monitor
- Crusher

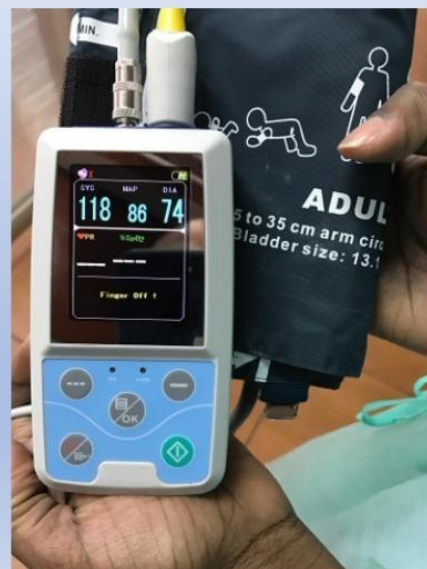

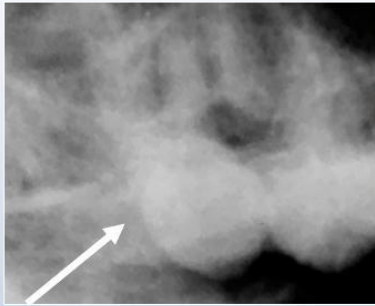


Blood pressure too high to treat him.

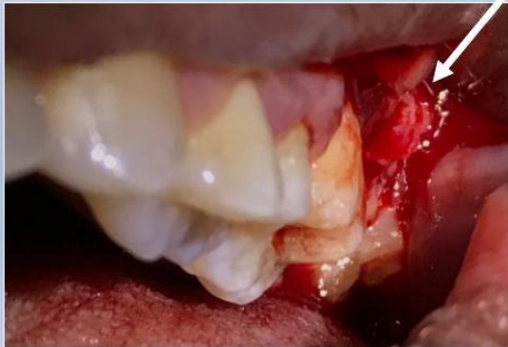

Oral sedation with the local approach, waited an hour, re-took the blood pressure, now in a normal range.



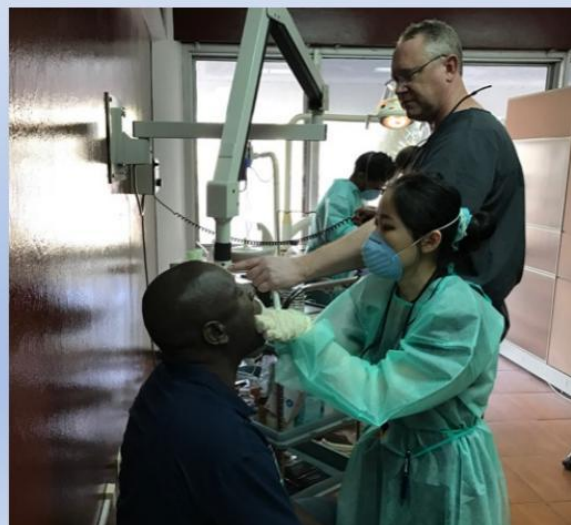
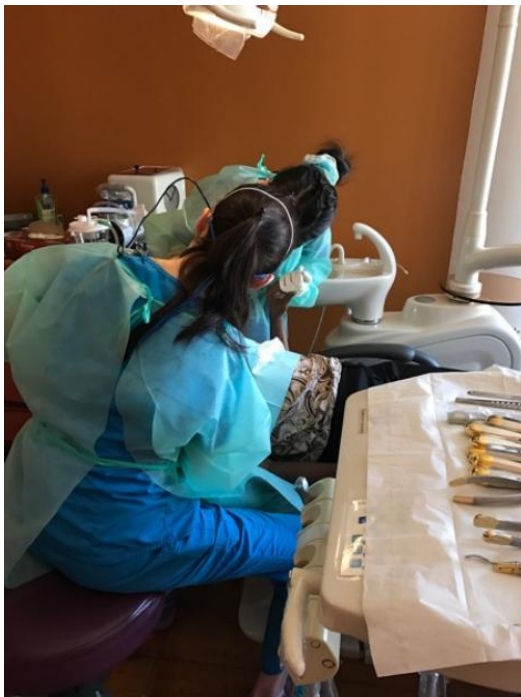
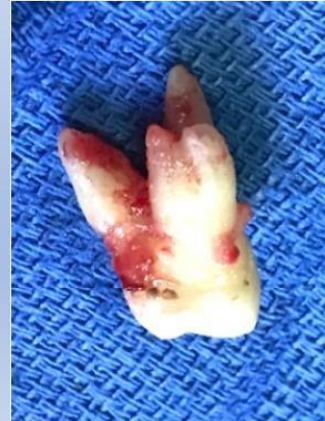
24 y.o. patient. Erupted upper third molar. Unusually thick bone on facial. Tooth would not luxate. Since it was a wisdom tooth... triangular flap, some buccal bone removal, tooth taken out via a buccal approach. Root tip

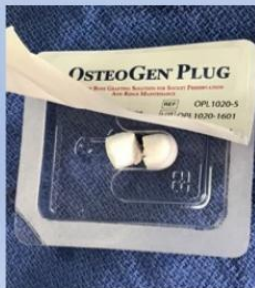
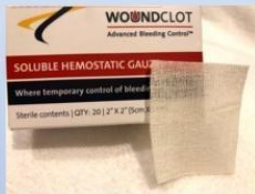
and was retrieved.

Tuberosity fracture avoided.



Some supplies on hand:



- WoundClot Hemostatic Gauze
- Osteogen Plugs
- Hedstrom files
- Surgical suction tips
- Emergency supplies, including oxygen tank, Epipen, inhaler, nitroglycerin, glucose, etc.